


A Comprehensive Approach to Glenohumeral Arthritis

October 2021

FEMKE VAN DREVEN MSC BSC (PHYSIO) MCSP

Twitter: @Durham_Physio

1

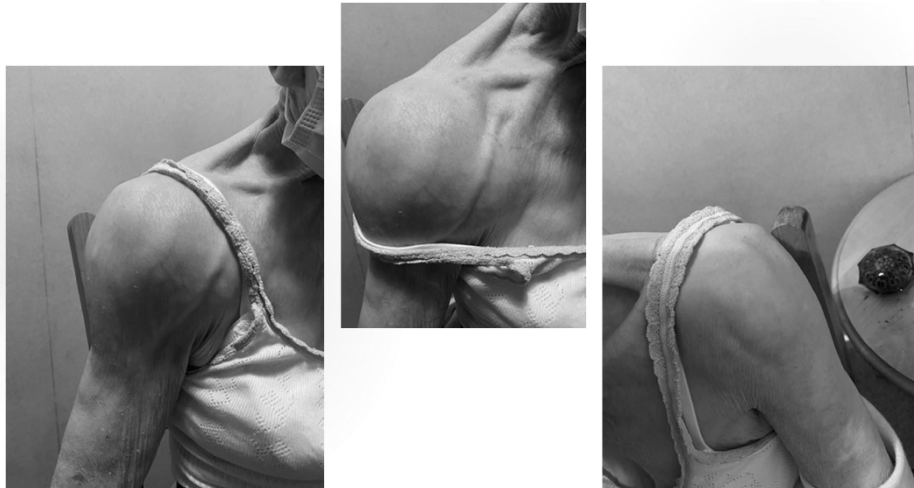

Case Study

- 93 year old lady, lives at home, 3 storey house
- Known osteoporosis, Alendronic Acid
- THR 2002, fractured pelvis 2014 (fall)
- Sensitivity to NSAIDs
- Paracetamol only
- 5+ year h/o shoulder pain, gradually worsening
- Uses w. frame in house, and sticks outside

2

Case Study



3

Reduced ROM

**(lack of passive)
ER – External Rotation**

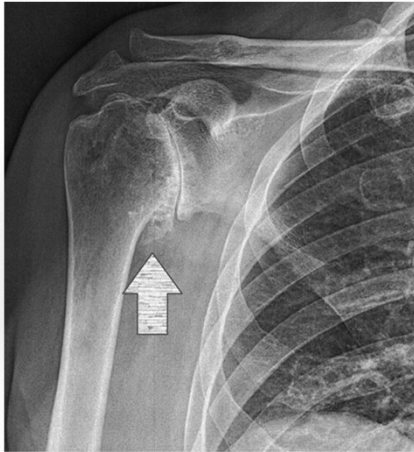
Weakness of RC

Anxious/Fearful

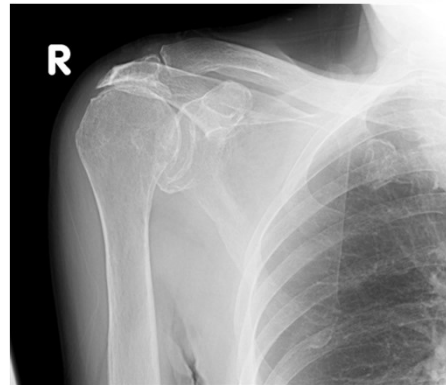


4

Case Study



(orthopaedicsone.com)



(orthobullets.com)

5

Differential Diagnosis

of the stiff shoulder

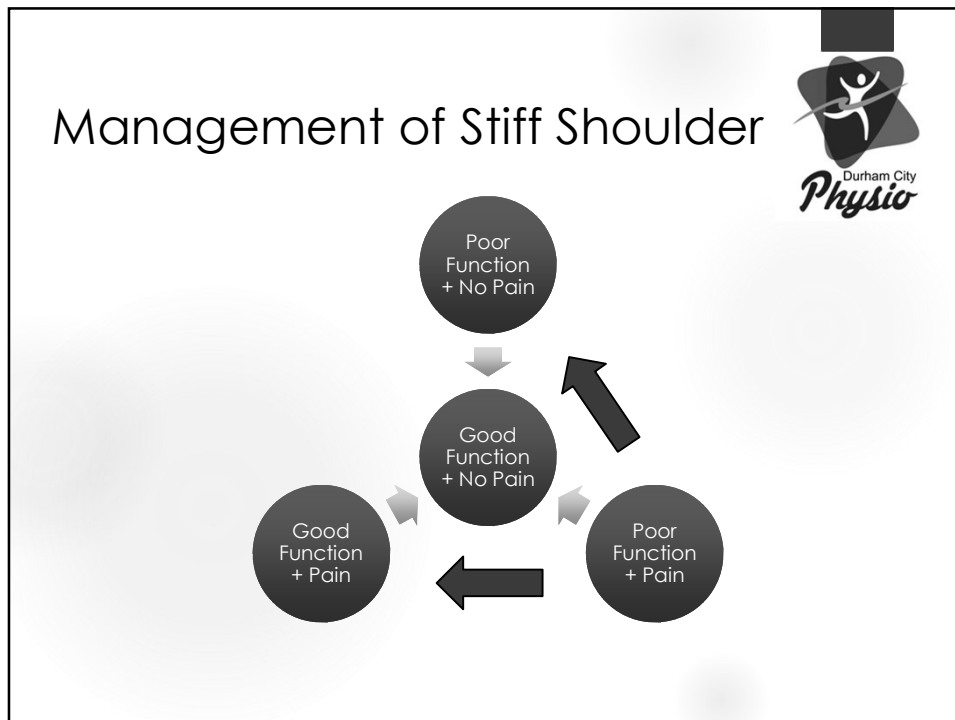


- Contracted Shoulder (=Frozen Shoulder)
more common in < 65 year olds
- Osteoarthritis (GH joint)
more common in 65+
- Cuff arthropathy
- Rheumatoid Arthritis/Polymyalgia Rheumatica
 - AVN (Avascular Necrosis)
more common 30 - 50
 - Infection
 - Tumours



Chillemi, Franceschini, 2013

6



7

Management

NON-SURGICAL

- NSAIDs/ Analgesics/ Amitriptyline 10-20mg) IP/ or liaise with GP
- **Corticosteroid injections (intra-articular)**
- Suprascapular Nerve Block/ Hyaluronic Acid
- **Modalities for pain relief (Acupuncture)**
- **Modalities for improving ROM/ Strength/ function**
 - Proximal stability before distal mobility
 - Full Kinetic Chain
 - Complex/Integrated strengthening better than isolated
 - Consider Zoom group classes

8

Management

SURGICAL



- Arthroscopic Debridement
- Humeral Head Resurfacing Arthroplasty
- Hemiarthroplasty
- Total Shoulder Arthroplasty
- Reverse Shoulder Arthroplasty

*O'Connaire & Lewis, 2012. Stupay & Neviasser, 2015.
Thomas et al, 2016. Bryant et al, 2017.*

9

BOA/BESS Management Glenohumeral Arthritis



M MISCELLANEOUS

BESS
Evidence based knowledge



BESS/BOA Patient Care Pathways Glenohumeral osteoarthritis

Michael Thomas, Amit Bidwai, Amar Rangan, Jonathan L Rees,
Peter Brownson, Duncan Tennent, Clare Connor and
Rohit Kulkarni


Shoulder & Elbow


Shoulder & Elbow
2016, Vol. 8(2) 203-214
© The Author(s) 2016
Reprints and permissions:
sagepub.co.uk/journalsPermissions.nav
DOI: 10.1177/1758373216644183
sagepub.com

SAGE

10

BOA/ BESS Management for Shoulder Pain





- Is there a positive cross arm test?
- Is there external rotation pain?
- Is there a painful arc of abduction?

Refer


Glenohumeral Joint

- If frozen shoulder with normal x-ray – refer if atypical and/or severe functional limitation.
- Refer if arthritis on x-ray and poor response to analgesics and injection.

Rotator Cuff Tendinopathy

11

Take Home Message



- ▶ Physiotherapists, Carers, Occupational Therapists
- ▶ ? Case Study
- ▶ #OlderPeoplesDay

[Older People's Day \(csp.org.uk\)](http://csp.org.uk)

12